



RESENTING CLINICAL SIGNS

DATE History: Pre-anesthetic evaluation. ECG showed an LAFB. No murmur.

ECHOCARDIOGRAPHIC FINDINGS

2D, M-mode, and Doppler study.

PERFORMED BY:

Dr. Meredith Swart

Left atrial size is normal. The mitral valve appears normal. Left ventricular wall thickness is normal. Left ventricular internal dimensions are normal. Left ventricular systolic function is normal. The aorta and aortic valve are normal. Right atrial and right ventricular dimensions are normal. The tricuspid valve appears normal. The pulmonary artery and pulmonic valve are normal. No shunting lesions are visualized. No pericardial effusion or cardiac masses are seen.

INTERPRETED BY

Keith Blass, DVM,
MS, DACVIM
(Cardiology)

LA/Ao - 1.29
IVSd - 5.2 mm
LVPWd - 4.8 mm
LVIDd - 16.6 mm
LVIDs - 8.5 mm
FS - 48.8%
LVOT - 0.95 m/s
RVOT - 1.01 m/s

PATIENT

Tony Walker

ASSESSMENT/RECOMMENDATIONS

SPECIES

Normal echocardiogram

Feline

This examination demonstrates no evidence of structural heart disease. As such, no reason for Tony's fascicular block is appreciated in the image set, and it's likely that the block is a normal variant.

BREED

Tony's cardiovascular risk for general anesthesia is low based on this exam, and there are no contraindications to the use of any specific anesthetic agents.

DSH

No therapy is recommended based on this exam.

SEX

A recheck echocardiogram is recommended if new physical exam and/or clinical abnormalities suggestive of cardiac dysfunction develop.

MN

AGE

13 y

WEIGHT

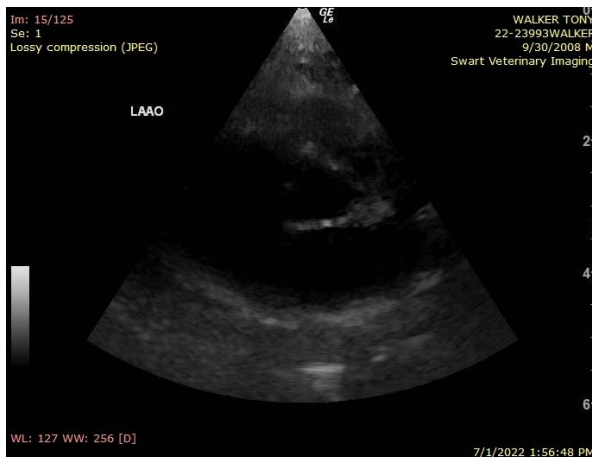11 lb

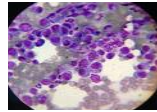
HOSPITAL NAME

Swart Veterinary
Imaging

REFERRING VET

Dr. Swart





DATE The information and recommendations provided are based on the images presented by the referring veterinarian. No evaluation can be communicated regarding pathology that was not visible in the image/video clips provided.

7/1/22

Thank you for this referral. If the clinical or image interpretation does not parallel your findings or if I can be of any further assistance please contact me.

PERFORMED BY:

Dr. Meredith Swart **Keith Blass, DVM, MS, DACVIM (Cardiology)**
KeithBlass@gmail.com
631-804-5754

INTERPRETED BY

Keith Blass, DVM,
MS, DACVIM
(Cardiology)

PATIENT

Tony Walker

SPECIES

Feline

BREED

DSH

SEX

MN

AGE

13 y

WEIGHT

11 lb

HOSPITAL NAME

Swart Veterinary
Imaging

REFERRING VET

Dr. Swart